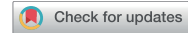



Inflammatory response to *Trichomonas vaginalis* in the pathogenesis of prostatitis and benign prostatic hyperplasia



Ik-Hwan Han^{1,2} , Jung-Hyun Kim^{1,2}, Jae-Sook Ryu^{1,2,*}

¹Department of Environmental Biology and Medical Parasitology, Hanyang University College of Medicine, Seoul 04763, Korea;

²Department of Biomedical Science, Graduate School of Biomedical Science & Engineering, Hanyang University College of Medicine, Seoul 04763, Korea

Abstract

Received: 23 November 2022

Accepted: 4 January 2023

*Correspondence
(jsryu@hanyang.ac.kr)

Citation

Han IH, Kim JH, Ryu JS. Inflammatory response to *Trichomonas vaginalis* in the pathogenesis of prostatitis and benign prostatic hyperplasia. Parasit Host Dis 2023;61(1):2-14.

Trichomonas vaginalis is a flagellated protozoan that causes trichomoniasis, a common nonviral sexually transmitted infection. *T. vaginalis* infection is asymptomatic in most infected men but can lead to chronic infection. The inflammatory response to chronic *T. vaginalis* infection may contribute to prostatic diseases, such as prostatitis and benign prostatic hyperplasia (BPH); however, studies on the relationship between *T. vaginalis* infection and prostate diseases are scarce. In this review, we discuss evidence from our studies on the involvement of *T. vaginalis* in the pathogenesis of prostate diseases, such as prostatitis and BPH. Studies of prostatitis have demonstrated that the attachment of *T. vaginalis* trophozoite to prostate epithelial cells (PECs) induces inflammatory cytokine production and inflammatory cell migration, leading to prostatitis. *T. vaginalis* also causes pathological changes, such as inflammatory cell infiltration, acinar changes, interstitial fibrosis, and mast cell infiltration, in prostate tissues of infected rats. Thus, *T. vaginalis* is considered an infectious agent that triggers prostatitis. Meanwhile, studies of prostatic hyperplasia revealed that mast cells activated by *T. vaginalis*-infected prostate cells secreted inflammatory mediators, such as β -hexosaminidase and trypsin, which promoted proliferation of prostate stromal cell (PSC). Moreover, interleukin-6 produced by proliferating PSCs induced the multiplication of BPH-1 epithelial cells as a result of stromal-epithelial interaction, suggesting that the proliferation of *T. vaginalis*-infected prostate cells can be induced through crosstalk with mast cells. These collective findings suggest that *T. vaginalis* contributes to the progression of prostatitis and prostatic hyperplasia by creating an inflammatory microenvironment involving PECs and PSCs.

Keywords: *Trichomonas vaginalis*, prostatitis, prostatic hyperplasia, inflammation, proliferation

Introduction

Trichomonas vaginalis is a flagellated protozoan belonging to the subphylum Mastigophora. Its total length, including the oval body, flagella, and axostyle, averages approximately 26 μm (21-32 μm). The body of *T. vaginalis* measures $9.5 \times 6.8 \mu\text{m}$, and the undulating membrane extends 3/4th of its body length [1]. *T. vaginalis* infects the urogenital system, causing trichomoniasis, and is the most common sexually transmitted protozoan. According to the World Health Organization estimates, the incidence of *T. vaginalis* infection is over 142 million cases [2]. In men, trichomoniasis causes pain during urination and ejaculation. Moreover, it increases the frequency of urination and results in a thin, white discharge from the penis as well as soreness, swelling, and redness around the head of the penis or foreskin. However, most *T. vaginalis* infections are asymptomatic, remain undiagnosed

© 2023 The Korean Society for Parasitology and Tropical Medicine

This is an Open Access article distributed under the terms of the Creative Commons Attribution Non-Commercial License (<https://creativecommons.org/licenses/by-nc/4.0>) which permits unrestricted non-commercial use, distribution, and reproduction in any medium, provided the original work is properly cited.

Author contributions

Conceptualization: Ryu JS
 Data curation: Kim JH
 Investigation: Han IH, Kim JH, Ryu JS
 Methodology: Han IH, Kim JH
 Supervision: Ryu JS
 Writing – original draft: Han IH, Ryu JS

Conflict of interest

The authors declare no conflict of interest related to this study.

ORCID

Ik-Hwan Han
 (<https://orcid.org/0000-0002-8145-6645>)
 Jae-Sook Ryu
 (<https://orcid.org/0000-0001-9145-7900>)

and untreated, and are thought to result in chronic persistent prostatic infection. In addition, trichomoniasis is a risk factor for human immunodeficiency virus transmission [3].

The prostate is a male urogenital organ located at the base of the bladder surrounding the urethra. It consists of 3 glandular zones, including the central, peripheral, and transition zones, along with a nonglandular region of the anterior prostate composed of fibromuscular stroma, which provides structural support [4]. The glandular tissue contributes to reproductive function by secreting zinc, citrate, and proteins, such as prostatic acid phosphatase, β -microsemiprotein, and prostatic-specific antigen, into the seminal fluid [5,6], whereas the fibromuscular tissue aids in the compartmentalization of fluids during urination and ejaculation.

Sfanos et al. [7] have suggested the existence of barrier functions and antimicrobial defenses in the prostate; epithelial cells in the prostate express pathogen pattern recognition receptors and Toll-like receptor 4 (TLR4), which may serve as defenses against prostate infections [8,9]. In addition, the prostatic fluid contains several antimicrobial proteins, such as lactoferrin, defensins, immunoglobulins, and complement proteins, as well as high levels of free zinc and citrate [10-12]. The strong antimicrobial activities of prostatic secretions may be important in the protection of the male genitourinary tract from ascending infections and sperm transiting into the female genital tract.

While microaerophilic *T. vaginalis* survive well in the vagina, which is essentially a hollow cavity, their survival becomes increasingly difficult once they reach the prostate, which contains antimicrobial proteins as well as high concentrations of zinc and citrate. Nevertheless, Gardner et al. [13] identified Tvs in the prostatic urethra, glandular lumina, submucosa, and stroma of 5 prostate glands obtained at autopsy via immunoperoxidase staining. The foci of nonspecific acute and chronic inflammation as well as intraepithelial vacuolization have also been reported to be associated with Tv infection. Moreover, Mitteregger detected Tv DNA in 34% of the prostate tissues obtained from 86 patients with benign prostatic hyperplasia (BPH), indicating that Tv is chronically present in BPH tissue and may influence prostate growth [14]. In addition, Iqbal et al. [15] detected *T. vaginalis* DNA and antigen in the prostate tissues of 42 (25%) and 37 (22%) patients with BPH, respectively.

Chronic infection with *T. vaginalis* may affect the development of prostatic hyperplasia as well as prostatitis. In this review, we discuss the hypothesis that *T. vaginalis* is involved in the initiation and/or progression of prostate diseases based on the results of both in vitro and in vivo experiments.

Prostatitis

Prostatitis is the most common urological diagnosis in men below 50 years of age, accounting for 8% of all office visits to urologists [16]. The most frequently diagnosed form of prostatitis is chronic prostatitis/chronic pelvic pain syndrome (CP/CPPS). However, despite its high prevalence, prostatitis remains poorly understood, and the majority of diagnosed cases are of unknown etiology. Predisposing factors for CP/CPPS include heredity, infection, voiding abnormalities, hormone imbalance, intraprostatic reflux, immunological/allergic triggers, and psychological factors. Infection is responsible for 71-74% of chronic prostatitis cases, with 11-19% cases resulting from trichomoniasis infection [17,18]. In Korea, the

prevalence of *T. vaginalis* infection, as determined via polymerase chain reaction, is 4 and 21% in patients with chronic prostatitis/urethritis and prostatic hyperplasia, respectively [19,20]. Despite these high prevalence rates, experimental induction of prostatic infection by *T. vaginalis* has not been attempted; however, it was determined whether exposure to *T. vaginalis* could induce an inflammatory response in normal prostate epithelial cells (PECs).

Adhesion of *T. vaginalis* to PECs and cytotoxic consequences

Alderete et al. [21,22] reported that the adhesion of *T. vaginalis* to mucosal cells is the first and essential step toward infection. Electron microscopy studies revealed that in vitro-grown *T. vaginalis* cells with a typical globular shape rapidly transform into flat and amoeboid cells upon contact with vaginal epithelial cells (VECs), maximizing the area of adhesion [23,24]. In contrast, little is known about the adherence of *T. vaginalis* to PECs. *T. vaginalis* stained with a CellTrackerOrange fluorescent probe was incubated with PECs (cell line RWPE-1) and observed under a fluorescence microscope. When PECs were incubated with *T. vaginalis* at ratios of 1:0.4 to 1:4, the adhesion of *T. vaginalis* began after 30 min and increased continuously for 24 h. When the number of trichomonads increased, the rate of adhesion to PECs also concomitantly increased [25]. At the RWPE-1: *T. vaginalis* ratio of 1:0.4, cytotoxic damage to PECs was evident at 9 h, whereas at the ratio of 1:4, it was observed at 3 h. Epithelial–mesenchymal transition (EMT) was confirmed by decreased E-cadherin expression and increased vimentin expression at 24 h [25,26], which was similar to that observed in type 2 EMT associated with wound healing and tissue regeneration.

When *T. vaginalis* attaches to PECs, it stimulates the production of IL-1 β , IL-6, CCL2, and CXCL8 by activating ROS, ERK, and NF- κ B signaling. Also, it has been reported that a PEC-conditioned medium containing these cytokines stimulates the migration of human neutrophils and monocytes. These data suggest that *T. vaginalis* induces an inflammatory response in PECs [27]. Because IL-1 β and IL-6 play important roles in the progression of prostatic diseases, the signaling pathways involved in the production of these cytokines during *T. vaginalis* infection of PECs were examined.

Involvement of the NLRP3 inflammasome in IL-1 β production by *T. vaginalis*-infected PECs

The NLRP3 inflammasome is involved in the production of IL-1 β , a mediator of prostate inflammation associated with BPH, chronic prostatitis, and chronic pelvic pain syndrome [28,29]. The secretion of IL-1 β is tightly regulated [30]. First, pro-IL-1 β is produced following the activation of pattern recognition receptors. This precursor is subsequently cleaved into a mature form by the proinflammatory cysteine protease caspase-1. Caspase-1 is activated in response to infection or tissue damage and is modulated by a macromolecular protein complex known as the inflammasome, which consists of a NOD-like receptor (NLR) family member, an adaptor protein, and an inactive caspase-1 precursor [31]. The NLRP3 inflammasome has been implicated in antibacterial, viral, fungal, and parasitic immune responses [32]. When PECs are infected with live *T. vaginalis*, the expression of ASC, NLRP3, and caspase-1, all of which are components of the NLRP3 inflammasome, increases. Conversely, IL-1 β production is decreased through siRNA-targeting of NLRP3 and caspase-1, confirming the involvement of the NLRP3 inflammasome in IL-1 β production [33].

Signaling pathway involved in IL-6 production by *T. vaginalis*-infected PECs

IL-6 is a well-known biomarker of chronic prostatic inflammation and a mediator of chronic inflammation in prostate cancer [34,35]. Sutcliffe et al. [36] suggested that IL-6 production in *T. vaginalis*-exposed PECs promotes prostate carcinogenesis through the expression of proto-oncogenes, such as PIM1, c-MYC, and HMGA1; however, nothing is known regarding the signal pathways involved in IL-6 production in response to *T. vaginalis*. Stimulation of PECs by *T. vaginalis* resulted in the increased production of IL-6; increased expression of TLR2, TLR4, MAPKs, NF- κ B, and JAK2/STAT3; and elevated levels of ROS. The inhibition of TLR2 or TLR4 reduced the production of IL-6 as well as the expression of other factors, and inhibitors of ROS, MAPKs, NF- κ B, and JAK reduced IL-6 production. PECs stimulated with *T. vaginalis* underwent EMT, which was suppressed by the inhibitors of JAK or NF- κ B. That is, *T. vaginalis* stimulates PECs to induce IL-6 production by activating TLR2/4, ROS, MAPKs, NF- κ B, AP-1, JAK2/STAT3, and EMT via the NF- κ B and JAK/STAT3 signaling pathways. Therefore, *T. vaginalis* may alter the prostate tumor microenvironment by inducing IL-6 production and EMT [26].

Prostate stromal inflammation in response to *T. vaginalis*

Prostatitis is caused by inflammatory responses that occurs not only in PECs but also in stromal cells. *T. vaginalis* has been detected in the submucosal layer and stroma of the prostate through immunoperoxidase staining [13]. The stromal compartment of the prostate primarily consists of smooth muscle cells, fibroblasts, macrophages, endothelial cells, and other immune cells [37]. The WPMY-1 cell line, isolated from normal human prostate stroma, is a myofibroblast line immortalized with SV40 large T antigen. Myofibroblasts play an important role in wound contraction in fibrotic diseases as an intermediate cell type between fibroblast and smooth muscle cell. Moreover, myofibroblasts are the dominant cell type associated with prostatic hypertrophy and contribute to prostate cancer progression and metastasis [38].

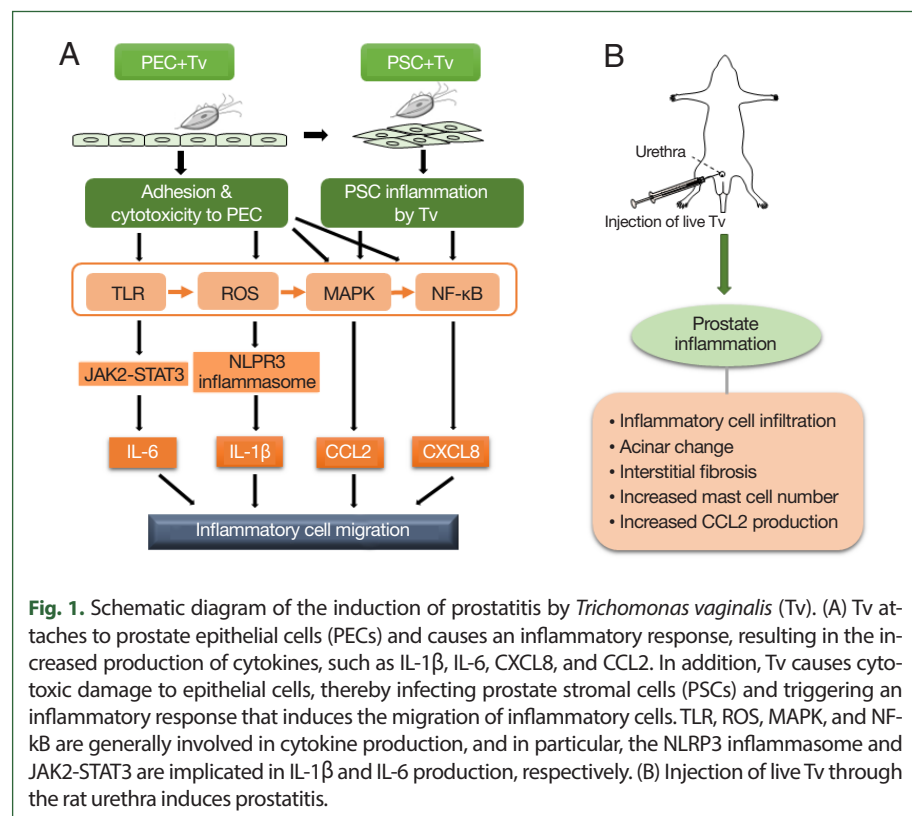
Previous studies showed that when RWPE-1 cells were incubated with *T. vaginalis*, cell viability at 24 h decreased concomitantly with an increase in the number of trichomonads, confirming that *T. vaginalis* is cytotoxic to RWPE-1 [25,26]. Sfanos et al. [7] suggested that epithelial cell death and consequent barrier function disruption lead to infiltration of stromal compartments by commensal or pathogenic organisms. It has been hypothesized that *T. vaginalis* penetrates the epithelium, enters the stroma, and induces an inflammatory response. Therefore, it was determined whether *T. vaginalis* induces an inflammatory response in stromal cells. Incubation of WPMY-1 with live *T. vaginalis* increased the expression of the inflammatory chemokines CXCL8 and CCL2. In addition, TLR4, ROS, MAPK, and NF- κ B expression increased, whereas the inhibitors of TLR4, ROS, MAPKs, and NF- κ B decreased CXCL8 and CCL2 production. Conditioned medium derived from WPMY-1 cells incubated with *T. vaginalis* stimulated the migration of human neutrophils and monocytes, suggesting that *T. vaginalis* increases CXCL8 and CCL2 production by human prostate stromal cells by activating TLR4, ROS, MAPKs and NF- κ B. This, in turn, attracts neutrophils and monocytes and results in an inflammatory response [39].

T. vaginalis infection causes rat prostatitis

The in vitro inflammatory responses induced by *T. vaginalis* in PECs and stromal cells prompted us to determine whether *T. vaginalis* causes prostatitis in an animal model. To mimic the route of *T. vaginalis* infection in humans, *T. vaginalis* was injected through the urethras of Wistar rats. *T. vaginalis* trophozoites were observed in the prostate acini of the injected rats via immunohistochemistry. The prostate tissues exhibited elevated pathological scores, and 83% (5/6 samples) and 100% (6/6 samples) of the ventral and dorsolateral lobes ($n = 6$), respectively, were inflamed. Pathological changes, such as inflammatory cell infiltration, acinar changes, and interstitial fibrosis, were observed. The inflammation was more severe in the dorsolateral lobes than in the ventral lobes. Moreover, infiltration and degranulation of mast cells were observed at higher rates in the prostate sections of the *T. vaginalis*-infected rats, and the prostate tissues of the injected rats had increased CCL2 levels. These findings provided the first evidence that *T. vaginalis* infection in rats causes prostatitis [40].

Summary of prostatitis experiments

Taken together, the above results indicate that the mechanism by which *T. vaginalis* causes prostatitis may occur as follows: *T. vaginalis* causes prostatitis by attaching to prostate cells and inducing proinflammatory cytokine production, inflammatory cell migration, and EMT. In animal experiments, injection of *T. vaginalis* into rats via the urethra caused prostatitis as evidenced by various pathologic changes, including inflammatory cell infiltration, acinar changes, interstitial fibrosis, mast cell infiltration, and increased CCL2 production.



These in vitro and in vivo experimental evidence demonstrate that *T. vaginalis* is an infectious agent causing prostatitis (Fig. 1).

Prostate Hyperplasia

Benign prostate hyperplasia (BPH)

BPH results in the benign enlargement of the prostate gland due to the unregulated hyperplastic growth of the epithelial and fibromuscular tissues of the transition zone and periurethral area [41]. BPH is an immune-mediated inflammatory disease, with persistent prostatic inflammation as a key factor in its development and progression [42,43]. An inflammatory reaction may be triggered by several factors, including bacterial infection (e.g., *Escherichia coli*), viruses (e.g., human papilloma virus, herpes simplex virus type 2, and cytomegalovirus), sexually transmitted organisms (e.g., gonorrhea and chlamydia), hormones, dietary factors, autoimmune response, and urinary reflux into the prostate collection ducts [42,44-46]. The inflammatory response induced by these factors may cause T-lymphocyte infiltration, cytokine production, growth factor expression, local hypoxia with angiogenesis, tissue damage with abnormal wound healing and stromal and epithelial cell proliferation, and eventually BPH [42,45].

Several sexually transmitted micro organisms, such as *Neisseria gonorrhoeae*, *Chlamydia trachomatis*, and *T. vaginalis*, are known to cause chronic inflammation of the prostate tissue [47]. However, in a study investigating the association between BPH (or lower urinary tract symptom-related outcomes) and antibodies against various sexually transmitted infections (e.g., *C. trachomatis*, *T. vaginalis*, human papilloma virus, herpes simplex virus, cytomegalovirus infection, gonorrhea, and syphilis), only *T. vaginalis* infection was found to be linked to BPH [48]. Moreover, *T. vaginalis* DNA was detected in the prostate tissue and urine of patients with BPH, suggesting that it acts as an initial stimulus for an inflammatory response [14,15,19]. In addition, Twu et al. [48] reported that *T. vaginalis* macrophage migration inhibitory factor induced an inflammatory response, prostate cell growth, and invasiveness in BPH-1 and prostate cancer cell lines.

To date, there have been few studies regarding prostate growth induced by the inflammatory response of prostate cells infected with live *T. vaginalis*. Claus et al. [50] reported that the proliferation rates of prostate epithelium and stroma increased by approximately 9-fold and 37-fold, respectively, in BPH compared with the normal prostate and that prostatic stromal hyperproliferation was an important feature of BPH pathogenesis. We focused on stromal hyperplasia in the experimental studies of prostatic hyperplasia.

We hypothesized that the crosstalk between prostatic cells inflamed by *T. vaginalis* infection and migrating inflammatory cells was involved in the proliferation of prostatic cells. During inflammatory reaction in prostate tissue, T lymphocytes are the most common infiltrating cells. B lymphocytes and macrophages are also known to infiltrate [42,44]. However, clinical studies have suggested that mast cells play an important role in the development and persistence of inflammation in BPH associated with the lower urinary tract [51-53]. In our prostate proliferation studies, we focused on mast cells based on reports that they are involved in the inflammatory response to *T. vaginalis* infection. Mast cells were preferentially detected in cervical smears from women with trichomoniasis compared with smears

from patients with vaginitis caused by other pathogens [54]. *T. vaginalis* (live trophozoites, excretory-secretory products [ESP]) was confirmed to induce an inflammatory response by migrating and activating mast cells, which resulted in the production of histamine and TNF- α [55]. When VECs were cocultured with *T. vaginalis*, VEC-produced inflammatory mediators activated and attracted mast cells and stimulated them to induce neutrophil migration [56]. In addition, the number of mast cells and activated degranulated mast cells increased during prostatitis in *T. vaginalis*-infected rats [40].

Mast cells are important cellular sensors and regulators of inflammation, fibrosis, and smooth muscle cell contraction [53,57-59]. Activated mast cells release various factors, such as chymase, tryptases, and proteases, which can interact with the local tissue environment and lead to tissue fibrosis, repair, and remodeling [53]. Conversely, little is known regarding the role of mast cells in prostate proliferation resulting from *T. vaginalis* infection.

Proliferation of stromal cells is induced by crosstalk between *T. vaginalis*-infected BPH epithelial cells and mast cells

T. vaginalis-infected BPH epithelial cells have been reported to produce cytokines, such as CXCL8, CCL2, IL-1 β , and IL-6, through the ROS, MAPK, and NF- κ B signaling pathways. Inflammatory mediators, including these cytokines, stimulate the migration of monocytes and mast cells. When mast cells are incubated with trichomonad-conditioned medium, the activated mast cells produce β -hexosaminidase and CXCL8 and induce PSC proliferation. Proliferation was decreased by inhibiting CXCR1 (receptor for CXCL8) and CCR2 (receptor for CCL2), indicating that CXCL8 and CCL2 stimulate PSC proliferation by binding to CXCR1 and CCR2, respectively. This study indicated that *T. vaginalis*-infected BPH-1 cells activate mast cells, which release inflammatory mediators that induce PSC proliferation [60,61].

Induction of PSC proliferation by tryptase derived from activated mast cells

Tryptase is the most abundant serine proteinase found in the secretory granules of mast cells and has been reported to induce human lung fibroblast migration, myoblast proliferation, and cardiac fibroblast activation via protease-activated receptor 2 (PAR2) [62-64]. PAR2 is a G-protein-coupled receptor activated through proteolytic cleavage by serine proteases, including tryptase. PAR2 may be involved in tissue remodeling by inducing fibroblast migration, differentiation, and extracellular matrix production [65]. Roman et al. [66] suggested that PAR2 activation in the prostate contributes to the development of lower urinary tract dysfunction through proinflammatory as well as profibrotic pathways. Furthermore, activation of the tryptase-PAR2 axis is important for the onset of fibrosis.

Studies have examined whether tryptase released from mast cells activated by *T. vaginalis*-infected prostate stromal cells (PSC) promotes the proliferation of PSCs via protease-activated receptor 2 (PAR2). Inflammatory mediators derived from *T. vaginalis*-infected PSCs induced mast cell migration, tryptase production, and PSC proliferation. Signaling molecules involved in the tryptase-PAR2 pathway (e.g., PAR2, p-ERK, COX-2, 15d-PGJ2, and PPAR γ) were increased, and the inhibition of tryptase and signaling molecules inhibited proliferation. These results indicate that the interaction between *T. vaginalis*-infected PSCs and mast cells induces the proliferation of PSCs via the tryptase-PAR2 pathway [67].

Induction of PEC proliferation through stromal–epithelial cell interaction

According to the American Urological Association, BPH is defined as a histologic diagnosis and refers to the proliferation of smooth muscle and epithelial cells within the prostatic transition zone [68]. Although there are reports regarding the proliferation of prostate stromal cells, only limited information is available on the proliferation of PECs.

Stromal–epithelial interactions play an important regulatory role in the development of the prostate and in the maintenance of the adult prostate in health and disease [69]. Siejka et al. [70] reported that bidirectional stromal–epithelial interactions occur in the prostate gland. When the supernatants of prostate stromal cells (or BPH epithelial cells) were added to BPH epithelial cells (or prostate stromal cells), proliferation was increased. In BPH tissues, the ratio of stromal to epithelial cells reached a value of 5.

As discussed in Proliferation of stromal cells is induced by crosstalk between *T. vaginalis*-infected BPH epithelial cells and mast cells, the proliferation of prostate stromal cells is induced by BPH epithelial cells in response to *T. vaginalis* infection through crosstalk with mast cells. Subsequently, the effect of IL-6 released by proliferating stromal cells on the induction of BPH epithelial cells was determined. When culture supernatants of proliferating prostate stromal cells were added to BPH epithelial cells, the latter multiplied and cyclin D1, FGF2, and Bcl-2 expression increased. Blocking the IL-6 signaling pathway with anti-IL-6R antibody or a JAK1/2 inhibitor inhibited the proliferation of BPH epithelial cells and reduced the expression of IL-6, IL-6R, and STAT3. EMT was also detected in proliferating BPH epithelial cells, indicating that IL-6 released from proliferating prostate stromal cells induced by BPH epithelial cells infected with *T. vaginalis* promoted BPH epithelial cell multiplication [71]. This indicates that the inflammatory microenvironment of prostate stromal cells resulting from *T. vaginalis* infection promotes the proliferation of PECs through stromal–epithelial interaction.

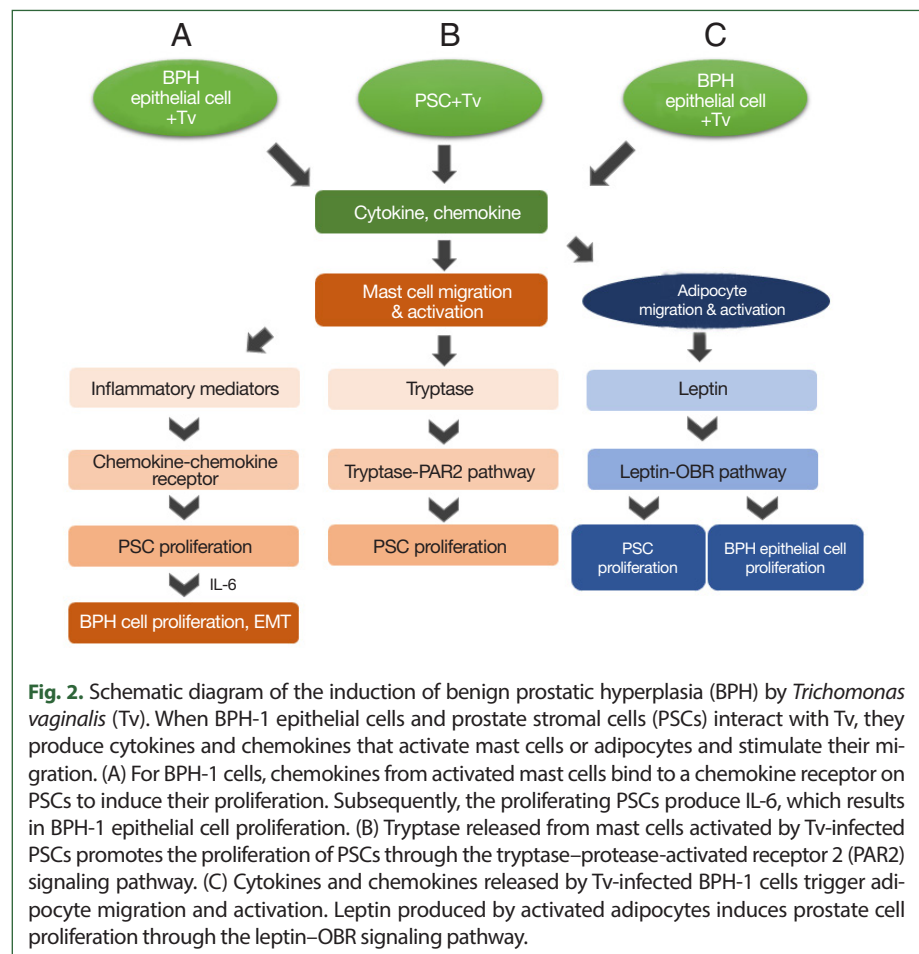
EMT is a complex process that involves the transformation of epithelial cells into stromal cells. It is integral to development, wound healing, and stem cell behavior, and it contributes to fibrosis and cancer progression [72,73]. Alonso-Magdalena et al. [74] analyzed prostate samples from 16 patients with BPH. BPH is not a disease of the prostate stroma but is the accumulation of mesenchymal-like cells derived from the prostate epithelium, suggesting that EMT plays an important role in the development of BPH. Shi et al. [75] and Hu et al. [76] reported that estradiol and TGF- β 1/Smad induce EMT in BPH epithelial cells. Thus, EMT in BPH epithelial cells proliferating in response to IL-6 produced by *T. vaginalis*-infected stromal cells is involved in the pathogenesis of BPH.

Involvement of adipocyte leptin in *T. vaginalis*-induced proliferation of prostate cells

BPH may be linked to obesity as abdominal obesity and serum leptin levels were found to be associated with prostate growth in a retrospective cohort study in Korea [77]. Male obesity has also been linked to increased severity of lower urinary tract symptoms (LUTS) in men affected by BPH [78]. Adipocytes, also known as lipocytes or fat cells, are the main components of adipose tissue that specialize in storing energy as fat. Adipokines produced by adipose tissue affect metabolic processes and mediate inflammation, cell proliferation, and angiogenesis [79]. Leptin is an adipokine originally identified as a key molecule regu-

lating food intake and body weight. It interacts with other hormones and energy regulators to mediate the effects of insulin, glucagon, insulin-like growth factor, growth hormone, glucocorticoids, cytokines, and metabolites [80]. Leptin also stimulates the growth of prostate, breast, lung, ovarian, and pancreatic cancer cells [81]. Prostate cells proliferate when leptin is administered together with estrogen; however, reports of prostate cell proliferation in response to leptin alone are rare [82].

A study was performed to determine whether *T. vaginalis*-infected BPH epithelial cells (BPH-1 cells) induced the proliferation of prostate cells through a leptin signaling pathway. BPH-1 cells incubated with live *T. vaginalis* released proinflammatory cytokines, and conditioned medium from these cells stimulated adipocyte migration. When PSCs and BPH-1 cells were incubated with adipocyte-conditioned medium containing leptin (ATCM), their growth rates increased. In addition, the expression of the leptin receptor (known as OBR) and downstream signaling molecules, such as JAK2/STAT3, Notch1/Jagged1, and survivin, increased. Moreover, OBR blocking reduced proliferation and the expression of leptin signaling molecules in response to ATCM. These findings indicate that inflamed BPH-1 cells infected with *T. vaginalis* promote prostate cell proliferation through leptin–OBR signaling. Therefore, it is likely that *T. vaginalis* contributes to prostate enlargement in BPH via adipocyte leptin release as a result of prostate inflammation [83].



Summary of prostate cell proliferation experiments

Based on the above results, the mechanism by which *T. vaginalis* induces prostate cell proliferation may be as follows: when *T. vaginalis* interacts with prostate cells, it triggers an inflammatory response, and migratory mast cells induce PSC proliferation by secreting inflammatory mediators or producing tryptase. Subsequently, the proliferating PSCs produce IL-6, which stimulates BPH-1 epithelial cell proliferation. These findings indicate that bidirectional stromal–epithelial interactions are responsible for PEC proliferation. In addition, when BPH-1 cells are infected with *T. vaginalis*, adipocytes migrate and produce leptin, which results in the proliferation of prostate cells through the leptin–OBR signaling pathway (Fig. 2). Taken together, it appears that *T. vaginalis* causes proliferation of the prostate via the infiltration of inflammatory cells, including mast cells and adipocytes.

Conclusion

When *T. vaginalis* interacts with prostate cells, such as PECs, prostate stromal cells, or BPH epithelial cells, inflammatory mediators such as cytokines are produced to create an inflammatory microenvironment. In addition, the inflammatory mediators released from activated inflammatory cells, including migratory mast cells and adipocytes, amplify the inflammatory response via cell–cell interactions, leading to prostatitis or BPH. Although this review highlights some pathogen-induced prostate inflammatory responses, more studies in this field are needed.

Acknowledgments

We thank Min-Young Seo, Su-Jeong Lim, Na-Young Gu, Sang-Su Kim, Hyo-Yeoung Chung, Dr. Kyu-Shik Kim, Dr. Ik-Hwan Han, Dr. Jung-Hyun Kim, and the late Dr. Ki-Seok Jang for participating in the experiments. Also we would like to thank Professor Soon-Jung Park for revising this review.

References

- Cheon SH, Kim SR, Song HO, Ahn MH, Ryu JS. The dimension of *Trichomonas vaginalis* as measured by scanning electron microscopy. *Korean J Parasitol* 2013;51(2):243-246. <http://doi.org/10.3347/kjp.2013.51.2.243>
- World Health Organization. Global health sectors strategy on sexually transmitted infections 2016-2021. World Health Organization. Geneva, Switzerland. 2016.
- McClelland RS, Sangare L, Hassan WM, Lavreys L, Mandaliya K, et al. Infection with *Trichomonas vaginalis* increases the risk of HIV-1 acquisition. *J Infect Dis* 2007;195(5):698-702. <http://doi.org/10.1086/511278>
- McNeal JE. Anatomy of the prostate and morphogenesis of BPH. *Prog Clin Biol Res* 1984;145:27-53.
- Leach DA, Need EF, Toivanen R, Trotta AP, Palethorpe HM, et al. Stromal androgen receptor regulates the composition of the microenvironment to influence prostate cancer outcome. *Oncotarget* 2015;6(18):16135-16150. <http://doi.org/10.18632/oncotarget.3873>
- Lilja H, Abrahamsson PA. Three predominant proteins secreted by the human prostate gland. *Prostate* 1988;12(1):29-38. <http://doi.org/10.1002/pros.2990120105>
- Sfanos KS, Yegnasubramanian S, Nelson WG, De Marzo AM. The inflammatory microenvironment and microbiome in prostate cancer development. *Nat Rev Urol* 2018;15(1):11-24 <http://doi.org/10.1038/nrurol.2017.167>
- Gatti G, Quintar AA, Andreani V, Nicola JP, Maldonado CA, et al. Expression of Toll-like receptor 4 in the prostate gland and its association with the severity of prostate cancer. *Prostate* 2009;69(13):1387-1397. <http://doi.org/10.1002/pros.20984>
- Gambara G, De Cesaris P, De Nunzio C, Ziparo E, Tubaro A, et al. Toll-like receptors in prostate infection and cancer between bench and bedside. *J Cell Mol Med* 2013;17(6):713-722.

- <http://doi.org/10.1111/jcmm.12055>
10. Manning ML, Williams SA, Jelinek CA, Kostova MB, Denmeade SR. Proteolysis of complement factors iC3b and C5 by the serine protease prostate-specific antigen in prostatic fluid and seminal plasma. *J Immunol* 2013;190(6):2567-2574. <http://doi.org/10.4049/jimmunol.1200856>
 11. Fowler JE Jr, Mariano M. Longitudinal studies of prostatic fluid immunoglobulin in men with bacterial prostatitis. *J Urol* 1984;131(2):363-369. [http://doi.org/10.1016/s0022-5347\(17\)50387-0](http://doi.org/10.1016/s0022-5347(17)50387-0)
 12. Isaacs JT. Prostatic structure and function in relation to the etiology of prostatic cancer. *Prostate* 1983;4(4):351-366. <http://doi.org/10.1002/pros.2990040405>
 13. Gardner WA Jr, Culbertson DE, Bennett BD. *Trichomonas vaginalis* in the prostate gland. *Arch Pathol Lab Med* 1986;110(5):430-432.
 14. Mitteregger D, Aberle SW, Makristathis A, Walochnik J, Brozek W, et al. High detection rate of *Trichomonas vaginalis* in benign hyperplastic prostatic tissue. *Med Microbiol Immunol* 2012;20(1):113-116. <http://doi.org/10.1007/s00430-011-0205-2>
 15. Iqbal J, Al-Rashed J, Kehinde EO. Detection of *Trichomonas vaginalis* in prostate tissue and serostatus in patients with asymptomatic benign prostatic hyperplasia. *BMC Infect Dis* 2016;16(1):506. <http://doi.org/10.1186/s12879-016-1843-1>
 16. Thumbikat P, Shahrara S, Sobkoviak R, Done J, Pope RM, et al. Prostate secretions from men with chronic pelvic pain syndrome inhibit proinflammatory mediators. *J Urol* 2010;184(4):1536-1542. <http://doi.org/10.1016/j.juro.2010.05.086>
 17. Skerk V, Schönwald S, Krhen I, Markovinić L, Beus A, et al. Aetiology of chronic prostatitis. *Int J Antimicrob Agents* 2002;19(6):471-474. [https://doi.org/10.1016/S0924-8579\(02\)00087-0](https://doi.org/10.1016/S0924-8579(02)00087-0)
 18. Skerk V, Krhen I, Schonwald S, Cajic V, Markovinić L, et al. The role of unusual pathogens in prostatitis syndrome. *Int J Antimicrob Agents* 2004;24(suppl 1):53-56. <https://doi.org/10.1016/j.ijantimicag.2004.02.010>
 19. Lee JJ, Moon HS, Lee TY, Hwang HS, Ahn MH, et al. PCR for diagnosis of male *Trichomonas vaginalis* infection with chronic prostatitis and urethritis. *Korean J Parasitol* 2012;50(2):157-159. <https://doi.org/10.3347/kjp.2012.50.2.157>
 20. Seo JH, Yang HW, Joo SY, Song SM, Lee YR, et al. Prevalence of *Trichomonas vaginalis* by PCR in men attending a primary care urology clinic in South Korea. *Korean J Parasitol* 2014;52(5):551-555. <https://doi.org/10.3347/kjp.2014.52.5.551>
 21. Alderete JF, Pearlman E. Pathogenic *Trichomonas vaginalis* cytotoxicity to cell culture monolayers. *Br J Vener Dis* 1984;60(2):99-105. <https://doi.org/10.1136/sti.60.2.99>
 22. Alderete JF, Garza GE. Specific nature of *Trichomonas vaginalis* parasitism of host cell surfaces. *Infect Immun* 1985;50(3):701-708. <https://doi.org/10.1128/iai.50.3.701-708.1985>
 23. Arroyo R, Gonzalez-Robles A, Martinez-Palomo A, Alderete JF. Signalling of *Trichomonas vaginalis* for amoeboid transformation and adhesion synthesis follows cytoadherence. *Mol Microbiol* 1993;7(2):299-309. <https://doi.org/10.1111/j.1365-2958.1993.tb01121.x>
 24. Kim SR, Ryu JS. Scanning electron microscopic observation of *Trichomonas vaginalis* contacted with human vaginal epithelial cells. *Korean J Electron Microscopy* 2001;31(3):235-244 (in Korean).
 25. Kim JH, Han IH, Kim SS, Park SJ, Min DY, et al. Interaction between *Trichomonas vaginalis* and the Prostate Epithelium. *Korean J Parasitol* 2017;55(2):213-218. <https://doi.org/10.3347/kjp.2017.55.2.213>
 26. Han IH, Kim JH, Kim SS, Ahn MH, Ryu JS. Signalling pathways associated with IL-6 production and epithelial-mesenchymal transition induction in prostate epithelial cells stimulated with *Trichomonas vaginalis*. *Parasite Immunol* 2016;38(11):678-687. <https://doi.org/10.1111/pim.12357>
 27. Seo MY, Im SJ, Gu NY, Kim JH, Chung YH, et al. Inflammatory Response of Prostate Epithelial Cells to Stimulation by *Trichomonas vaginalis*. *Prostate* 2014;74:441-449. <https://doi.org/10.1002/pros.22766>
 28. Kashyap M, Pore S, Wang Z, Gingrich J, Yoshimura N, et al. Inflammasomes are important mediators of prostatic inflammation associated with BPH. *J Inflamm (Lond)* 2015;12:37. <https://doi.org/10.1186/s12950-015-0082-3>
 29. Chen CS, Chang PJ, Lin WY, Huang YC, Ho DR. Evidences of the inflammasome pathway in chronic prostatitis and chronic pelvic pain syndrome in an animal model. *Prostate* 2013;73(4):391-397. <https://doi.org/10.1002/pros.22580>
 30. Dinarello CA. Interleukin 1 and interleukin 18 as mediators of inflammation and the aging process. *Am J Clin Nutr* 2006;83(2):447S-455S. <https://doi.org/10.1002/pros.22580>
 31. Martinon F, Tschopp J. Inflammatory caspases: linking an intracellular innate immune system to autoinflammatory diseases. *Cell* 2004;117(5):561-574. <https://doi.org/10.1016/j.cell.2004.05.004>
 32. Elinav E, Strowig T, Henao-Mejia J, Flavell RA. Regulation of the antimicrobial response by NLR proteins. *Immunity* 2011;34(5):665-679. <https://doi.org/10.1016/j.immuni.2011.05.007>
 33. Gu NY, Kim JH, Han IH, Im SJ, Seo MY, et al. *Trichomonas vaginalis* induces IL-1 beta production in a human prostate epithelial cell line by activating the NLRP3 inflammasome via reactive oxygen species and potassium ion efflux. *Prostate* 2016;76(10):885-896. <https://doi.org/10.1002/pros.23178>
 34. Nguyen DP, Li JY, Tewari AK. Inflammation and prostate cancer: the role of interleukin 6 (IL-6). *BJU Int* 2014;113(6):986-992. <https://doi.org/10.1111/bju.12452>
 35. Bardan R, Dumache R, Dema A, Cumpănaș A, Bucur A. The role of prostatic inflammation biomarkers in the diagnosis of prostate diseases. *Clin Biochem* 2014;47(10-11):909-915. <https://doi.org/10.1016/j.clinbiochem.2014.02.008>
 36. Sutcliffe S, Neace C, Magnuson NS, Reeves R, Alderete JF. Trichomonosis, a common curable STI, and prostate carcinogenesis—a proposed molecular mechanism. *PLoS Pathog* 2012;8(8):e1002801. <https://doi.org/10.1371/journal.ppat.1002801>
 37. Thomson AA, Cunha GR, Marker PC. Prostate development

- and pathogenesis. *Differentiation* 2008;76(6):559-564. <https://doi.org/10.1111/j.1432-0436.2008.00303.x>
38. Tuxhorn JA, Ayala GE, Rowley DR. Reactive stroma in prostate cancer progression. *J Urol* 2001;166(6):2472-2483.
 39. Im SJ, Han IH, Kim JH, Gu NY, Seo MY, et al. Inflammatory response of a prostate stromal cell line induced by *Trichomonas vaginalis*. *Parasite Immunol* 2016;38(4):218-227. <https://doi.org/10.1111/pim.12308>
 40. Jang KS, Han IH, Lee SJ, Yoo J, Kim YS, et al. Experimental rat prostatitis caused by *Trichomonas vaginalis* infection. *Prostate* 2019;79(4):379-389. <https://doi.org/10.1002/pros.23744>
 41. Bostwick DG. The pathology of benign prostatic hyperplasia. In Kirby RS, McConnell JD, Fitzpatrick JM, Roehrborn CG, Boyle P, eds., *Textbook of Benign Prostate Hyperplasia* 6. 2nd ed. Isis Medical Media. London, UK. 2002, pp 97-112.
 42. De Nunzio C, Salonia A, Gacci M, Ficarra V. Inflammation is a target of medical treatment for lower urinary tract symptoms associated with benign prostatic hyperplasia. *World J Urol* 2020;38:2771-2779. <https://doi.org/10.1007/s00345-020-03106-1>
 43. Gravas S, Cornu JN, Gacci M, Gratzke C, Hermann TRW, et al. Management of Non-Neurogenic Male LUTS. EAU Guidelines Office. Arnhem, the Netherlands. 2022.
 44. Devlin CM, Simms MS, Maitland NJ. Benign prostatic hyperplasia - what do we know? *BJU Int* 2021;127(4):389-399. <https://doi.org/10.1111/bju.15229>
 45. De Nunzio C, Presicce F, Tubaro A. Inflammatory mediators in the development and progression of benign prostatic hyperplasia. *Nat Rev Urol* 2016;13(10):613-626. <https://doi.org/10.1038/nrurol.2016.168>
 46. Ficarra V, Sekulovic S, Zattoni F, Zazzera M, Novara G. Why and how to evaluate chronic prostatic inflammation. *Eur Urol Suppl* 2013;12(5):110-115. <https://doi.org/10.1016/j.eursup.2013.08.002>
 47. De Marzo AM, Platz EA, Sutcliffe S, Xu J, Gronberg H, et al. Inflammation in prostate carcinogenesis. *Nat Rev Cancer* 2007;7(4):256-269. <https://doi.org/10.1038/nrc2090>
 48. Breyer BN, Huang WY, Rabkin CS, Alderete JF, Pakpahan R, et al. Sexually transmitted infections, benign prostatic hyperplasia and lower urinary tract symptom-related outcomes: results from the prostate, lung, colorectal and ovarian cancer screening trial. *BJU Int* 2016;117(1):145-154. <https://doi.org/10.1111/bju.13050>
 49. Twu O, Dessi D, Vu A, Mercer F, Stevens GC, et al. *Trichomonas vaginalis* homolog of macrophage migration inhibitory factor induces prostate cell growth, invasiveness, and inflammatory responses. *Proc Natl Acad Sci U S A* 2014;111(22):8179-8184. <https://doi.org/10.1073/pnas.1321884111>
 50. Claus S, Wrenger M, Senge T, Schulze H. Immunohistochemical determination of age related proliferation rates in normal and benign hyperplastic human prostates. *Urol Res* 1993;21(5):305-308. <https://doi.org/10.1007/BF00296825>
 51. Ou Z, He Y, Qi L, Zu X, Wu L, et al. Infiltrating mast cells enhance benign prostatic hyperplasia through IL-6/STAT3/Cy-clin D1 signals. *Oncotarget* 2017;8(35):59156-59164. <https://doi.org/10.18632/oncotarget.19465>
 52. Romih R, Winder M, Lee G. Recent advances in the biology of the urothelium and applications for urinary bladder dysfunction. *Biomed Res Int* 2014;2014:341787. <https://doi.org/10.1155/2014/341787>
 53. Pattabiraman G, Bell-Cohn AJ, Murphy SF, Mazur DJ, Schaeffer AJ, et al. Mast cell function in prostate inflammation, fibrosis, and smooth muscle cell dysfunction. *Am J Physiol Renal Physiol* 2021;321(4):F466-F479. <https://doi.org/10.1152/ajprenal.00116.2021>
 54. Kobayashi TK, Fujimoto T, Okamoto H, Yuasa M, Sawaragi I. Association of mast cells with vaginal trichomoniasis in endocervical smears. *Acta cytol* 1983;27(2):133-137.
 55. Im SJ, Ahn MH, Han IH, Song HO, Kim YS, et al. Histamine and TNF-alpha release by rat peritoneal mast cells stimulated with *Trichomonas vaginalis*. *Parasite* 2011;18(1):49-55. <https://doi.org/10.1051/parasite/2011181049>
 56. Han IH, Park SJ, Ahn MH, Ryu JS. Involvement of mast cells in inflammation induced by *Trichomonas vaginalis* via cross-talk with vaginal epithelial cells. *Parasite Immunol* 2012;34(1):8-14. <https://doi.org/10.1111/j.1365-3024.2011.01338.x>
 57. Beghdadi W, Madjene LC, Benhamou M, Charles N, Gautier G, et al. Mast cells as cellular sensors in inflammation and immunity. *Front Immunol* 2011;2:37 <https://doi.org/10.3389/fimmu.2011.00037>
 58. Krystel-Whittemore M, Dileepan KN, Wood JG. Mast cell: a multi-functional master cell. *Front Immunol* 2015;6:620. <https://doi.org/10.3389/fimmu.2015.00620>
 59. Overed-Sayer C, Rapley L, Mustelin T, Clarke DL. Are mast cells instrumental for fibrotic diseases? *Front Pharmacol* 2014;4:174. <https://doi.org/10.3389/fphar.2013.00174>
 60. Kim SS, Kim JH, Han IH, Ahn MH, Ryu JS. Inflammatory responses in a benign prostatic hyperplasia epithelial cell line (BPH-1) infected with *Trichomonas vaginalis*. *Korean J Parasitol* 2016;54(2):123-132. <https://doi.org/10.3347/kjp.2016.54.2.123>
 61. Kim JH, Kim SS, Han IH, Sim S, Ahn MH, et al. Proliferation of prostate stromal cell induced by benign prostatic hyperplasia epithelial cell stimulated with *Trichomonas vaginalis* via cross-talk with mast cell. *Prostate* 2016;76(15):1431-1444. <https://doi.org/10.1002/pros.23227>
 62. Duchesne E, Tremblay MH, Cote CH. Mast cell tryptase stimulates myoblast proliferation; a mechanism relying on protease-activated receptor-2 and cyclooxygenase-2. *BMC Musculoskelet Disord* 2011;12:235 <https://doi.org/10.1186/1471-2474-12-235>
 63. Bagher M, Larsson-Callerfelt AK, Rosmark O, Hallgren O, Bjermer L, et al. Mast cells and mast cell tryptase enhance migration of human lung fibroblasts through protease-activated receptor 2. *Cell Commun Signal* 2018;16(1):59 <https://doi.org/10.1186/s12964-018-0269-3>
 64. Murray DB, McLarty-Williams J, Nagalla KT, Janicki JS. Tryptase

- ase activates isolated adult cardiac fibroblasts via protease activated receptor-2 (PAR-2). *J Cell Commun Signal* 2012;6(1):45-51 <https://doi.org/10.1007/s12079-011-0146-y>
65. Borensztajn K, Bresser P, van der Loos C, Bot I, van den Blink B, et al. Protease-activated receptor-2 induces myofibroblast differentiation and tissue factor up-regulation during bleomycin-induced lung injury: potential role in pulmonary fibrosis. *Am J Pathol* 2010;177(6):2753-2764. <https://doi.org/10.2353/ajpath.2010.091107>
 66. Roman K, Murphy SF, Done JD, McKenna KE, Schaeffer AJ, et al. Role of PAR2 in the development of lower urinary tract dysfunction. *J Urol* 2016;196(2):588-598. <https://doi.org/10.1016/j.juro.2016.01.106>
 67. Noh CS, Chung HY, Han IH, Kim JH, Kim YM, et al. Mast cell tryptase-PAR2 pathway in proliferation of prostatic stromal cells reacted with *Trichomonas vaginalis*. *Parasite Immunol* 2021;43(8):e12868. <https://doi.org/10.1111/pim.12868>
 68. Lokeshwar SD, Harper BT, Webb E, Jordan A, Dykes TA, et al. Epidemiology and treatment modalities for the management of benign prostatic hyperplasia. *Transl Androl Urol* 2019;8(5):529-539. <https://doi.org/10.21037/tau.2019.10.01>
 69. Kogan-Sakin I, Cohen M, Paland N, Madar S, Solomon H, et al. Prostate stromal cells produce CXCL-1, CXCL-2, CXCL-3 and IL-8 in response to epithelia-secreted IL-1. *Carcinogenesis* 2009;30(4):698-705. <https://doi.org/10.1093/carcin/bgp043>
 70. Siejka A, Schally AV, Barabutis N. The effect of LHRH antagonist cetrorelix in crossover conditioned media from epithelial (BPH-1) and stromal (WPMY-1) prostate cells. *Horm Metab Res* 2014;46(1):21-26. <https://doi.org/10.1055/s-0033-1349127>
 71. Kim JH, Han IH, Kim YS, Noh CS, Ryu JS. Proliferation of prostate epithelia induced by IL-6 from stroma reacted with *Trichomonas vaginalis*. *Parasite Immunol* 2018;40(6):e12531. <https://doi.org/10.1111/pim.12531>
 72. Lamouille S, Xu J, Derynck R. Molecular mechanisms of epithelial-mesenchymal transition. *Nat Rev Mol Cell Biol* 2014;15:178-196. <https://doi.org/10.1038/nrm3758>
 73. Han IH, Kim JH, Jang KS, Ryu JS. Inflammatory mediators of prostate epithelial cells stimulated with *Trichomonas vaginalis* promote proliferative and invasive properties of prostate cancer cells. *Prostate* 2019;79(10):1133-1146. <https://doi.org/10.1002/pros.23826>
 74. Alonso-Magdalena P, Brossner C, Reiner A, Cheng G, Sugiyama N, et al. A role for epithelial-mesenchymal transition in the etiology of benign prostatic hyperplasia. *Proc Natl Acad Sci U S A* 2009;106(8):2859-2863. <https://doi.org/10.1073/pnas.0812666106>
 75. Shi X, Peng Y, Du X, Liu H, Klocker H, et al. Estradiol promotes epithelial-to-mesenchymal transition in human benign prostatic epithelial cells. *Prostate* 2017;77(14):1424-1437. <https://doi.org/10.1002/pros.23404>
 76. Hu S, Yu W, Lv TJ, Chang CS, Li X, et al. Evidence of TGF-B1 mediated epithelial-mesenchymal transition in immortalized benign prostatic hyperplasia cells. *Mol Mem Biol* 2014;31(2-3):103-110. <https://doi.org/10.3109/09687688.2014.894211>
 77. Jung JH, Ahn SV, Song JM, Chang SJ, Kim KJ, et al. Obesity as a risk factor for prostatic enlargement: a retrospective cohort study in Korea. *Int Neurourol J* 2016;20(4):321-328. <https://doi.org/10.5213/inj.1632584.292>
 78. Lee RK, Chung D, Chughtai B, Te AE, Kaplan SA. Central obesity as measured by waist circumference is predictive of severity of lower urinary tract symptoms. *BJU Int* 2012;110(4):540-545. <https://doi.org/10.1111/j.1464-410X.2011.10819.x>
 79. Sieminska L, Borowski A, Marek B, Nowak M, Kajdaniuk D, et al. Serum concentrations of adipokines in men with prostate cancer and benign prostate hyperplasia. *Endokrynol Pol* 2018;69(2):120-127. <https://doi.org/10.5603/EP.a2018.0006>
 80. Margetic S, Gazzola C, Pegg GG, Hill RA. Leptin: a review of its peripheral actions and interactions. *Int J Obes Relat Metab Disord* 2002;26:1407-1433. <https://doi.org/10.1038/sj.ijo.0802142>
 81. Szyszka M, Tyczewska M, Milecka P, Jopek K, Celichowski P, et al. Effects of leptin on leptin receptor isoform expression and proliferative activity in human normal prostate and prostate cancer cell lines. *Oncol Rep* 2018;39(1):182-192. <https://doi.org/10.3892/or.2017.6066>
 82. Habib CN, Al-Abd AM, Tolba MF, Khalifa AE, Khedr A, et al. Leptin influences estrogen metabolism and accelerates prostate cell proliferation. *Life Sci* 2015;121:10-15. <https://doi.org/10.1016/j.lfs.2014.11.007>
 83. Kim JH, Han IH, Shin SJ, Park SY, Chung HY, et al. Signaling role of adipocyte leptin in prostate cell proliferation induced by *Trichomonas vaginalis*. *Korean J Parasitol* 2021;59(3):235-249. <https://doi.org/10.3347/kjp.2021.59.3.235>